

case report

FUNGAL BEZOAR AS AN ATYPICAL CAUSE OF DISTAL URETERAL STENOSIS: REPORT OF A CASE FROM THE SURGICAL PERSPECTIVE

FUNGÁLNY BEZOÁR AKO ZRIEDKAVÁ PRÍČINA STENÓZY DISTÁLNEHO MOČOVODU: POPIS KAZUISTIKY Z POHLĀDU CHIRURGICKEJ LIEČBY

Peter Weibl, Tobias Klatter, Matthias Waldert

Department of Urology, Medical University of Vienna, Währinger Gürtel 18-20, Austria

Received: 24. 6. 2012.

Accepted: 2. 10. 2012.

Corresponding author:

Peter Weibl MD, PhD

Department of Urology University of Vienna

Währinger Gürtel 18-20, A 1090 Vienna

Austria

e-mail: pweibl@yahoo.com

Conflict of interest: The authors declare no conflict of interest.

Summary

Weibl P, Klatter T, Waldert M. Fungal bezoar as an atypical cause of distal ureteral stenosis: report of a case from the surgical perspective

The authors describe a case of an atypical fungal bezoar of the bladder in the area of the right ureteral orifice with consecutive hydronephrosis. The further management from

surgical perspective is discussed when hydronephrosis after transurethral resection of the bladder (TUR-B) and systemic treatment with antifungal triazol (voriconazole) persisted.

Key words:

bladder bezoar, fungal bezoar, distal ureteral stenosis

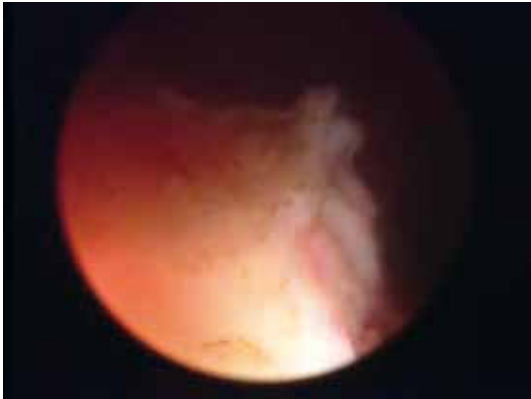
Souhrn

Weibl P, Klatter T, Waldert M. Fungálny bezoár ako zriedkavá príčina stenózy distálneho močovodu: popis kazuistiky z pohľadu chirurgickej liečby

Autori popisujú zriedkavý prípad fungálneho bezoáru močového mechúra v oblasti ústia pravého močovodu s následným rozvojom hydronefrózy. Možnosti následnej chirurgickej liečby po zlyhaní transuretrálnej resekcie močového mechúra (TUR-B) a systémovej antifungálnej terapie (voriconazolom) sú predmetom ďalšej diskusie

Klíčová slova:

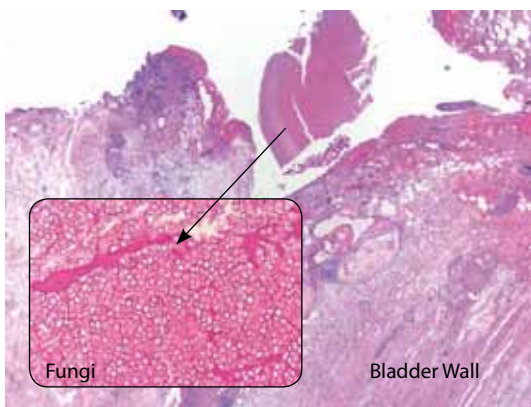
bezoár močového mechúra, fungálny bezoár, stenóza distálneho močovodu.

**Fig. 1.**

Solid „fungal“ mass in the area of the right ureteral orifice

Obr. 1.

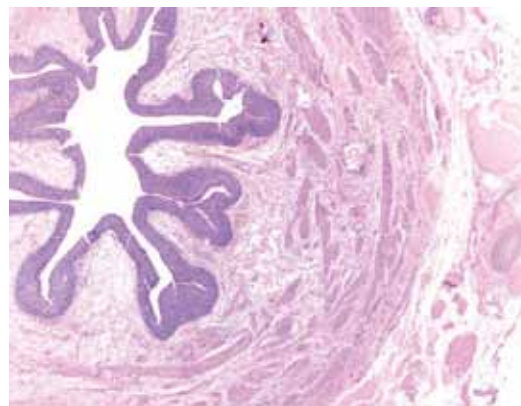
Solídna masa v oblasti ústia pravého močovodu

**Fig. 2.**

Fungal bezoar of the bladder (*Aspergillus*, *Candida* – antibody, antigens negative)

Obr. 2.

Fungálny bezoár močového mechúra (*Aspergillus*, *Candida* protilátky antigén-negatívne)

**Fig. 3.**

Extensive edema of the distal part of the resected right ureter without histopathological features of fungal infection

Obr. 3.

Rozsiahly edém v distálnej časti resekovaného pravého močovodu bez histopatologického nálezu fungálnej infekcie

INTRODUCTION

Obstruction of the upper urinary tract caused by fungal infection (fungus ball, bezoar) is a rare case scenario. Fungal infection is most commonly treated by systemic infusions with antifungal agent, or applied via nephrostomy tube and bladder irrigation. The authors describe a case of fungal bezoar of the bladder causing stenosis at the level of the right ureteral orifice. Despite the less invasive treatment, the patient was finally managed by open ureteral reimplantation. The potential treat-

ment options from the surgical perspective are a matter of further discussion.

CASE REPORT

A 76 years old female patient presented to our department with right flank pain. Renal ultrasound showed right-sided hydronephrosis. The patient had a history of 3 recent episodes of macroscopic haematuria. Apart from the clinical picture, the patient had arterial hypertension and was otherwise healthy. Cystoscopy

revealed an atypically shaped solid tumor in the area of the right ureteral orifice with its complete occlusion. Macroscopically, the mass was suspected of infiltrating the muscularis propria (Fig. 1). The orifice could not be identified, therefore the retrograde pyelography was unsuccessful. Laboratory findings were within normal limits apart from the serum creatinin (161,8 $\mu\text{mol/l}$), which was slightly elevated. Urinary cytology as well as the urinary culture were negative. A 4-phase computed tomography (CT) of the abdomen demonstrated a right-sided hydronephrosis, without any other abnormal findings. Gynaecological examination showed no pathology.

After the transurethral resection of the suspected bladder tumor (TUR-B), final histopathology showed fungal bezoar of the bladder wall without any specification (Fig. 2). An antifungal therapy with voriconazole 400mg i.v. once daily was initiated. The blood examination revealed *Aspergillus* and *Candida* antigens/antibodies as negative. CT scan of the thorax did not find any signs of fungal infection. The patient demonstrated symptoms of systemic infection (elevated CRP levels, chills and progressive right flank pain) on the postoperative day two (after TUR-B). A percutaneous nephrostomy tube was inserted under local anesthesia. Antegrade uretero-pyelography showed complete obstruction of the distal part of the ureter approximately 1cm from the orifice). Control contrast enhanced CT scan of the abdomen revealed only hydronephrosis without any other abnormalities. After antibiotic treatment we decided to proceed with an invasive surgical approach, which included - open excision of the distal part of the right ureter and ureteral reimplantation.

The postoperative course was uneventful, the patient was discharged one week after surgery. Urine culture, cytology as well as the follow up cystoscopy (after the period of 4 weeks, 6 and 12 months thereafter) were negative. Even though invasive surgery raises some questions, regarding why and when to stay more conservative. In the meantime there are no sufficient data where to rely on particular guidelines in terms of treatment. The final histopathology of our surgical specimen confirmed extensive edema of the ureter without any signs of fungal infection (Fig. 3).

DISCUSSION

We report on a case of fungal bezoar of the bladder causing distal ureteral stenosis. The patient was initially managed by TUR-B and antifungal therapy. Finally, open surgery with distal ureterectomy and ureteral reimplantation was necessary. In this particular scenario, we could be probably less invasive in our treatment strategy. Endoscopic management and eradication of bladder bezoars as well as invasive partial cystectomy have been described recently (1, 2). Our case raises few questions from the surgical perspective: 1) management with local irrigation via nephrostomy tube with antifungal agent; 2) antegrade flexible ureteroscopy and insertion of double J stent in an antegrade fashion, after the course of systemic and local antifungal treatment; 3) proceeding to alternative methods such as endoureterotomy with holmium laser, cold knife, resection loop; 4) second look TUR-B to confirm or exclude the presence of fungal infection or 5) invasive surgery. The majority of benign distal stenoses of the ureter are managed surgically. Stenting of the ureter relieves the hydronephrosis temporarily, however after its removal stenosis very often recurs. Therefore we presume that after unsuccessful TUR of the bladder with persistent complete ureteral stenosis, invasive surgery should be considered as the treatment option with long term success. We hypothesize that fungal infection together with an endoscopic procedure has a potential to develop recurrent stricture with irreversible tissue changes as we know from the common practice. But on the contrary we have to admit the fact that our case represents the opposite. That is why the stenting of the ureter in these particular cases like ours should precede invasive surgery. Before that, exclusion of fungal infection is mandatory (second TUR, retrograde or antegrade biopsy).

Surgical drainage and resection of infected tissue is often required and is commonly used as initial step to establish a diagnosis. If obstruction with a fungus ball leads to hydronephrosis, the safe and efficient treatment involves systemic treatment and irrigation via nephrostomy catheter with an antifungal agent (3). The fungus in the bladder may be eradicated endoscopically. If this fails, surgical management should be reconsidered.

LITERATURA

1. **Modi P, Goel R.** Synchronous endoscopic management of bilateral kidney and ureter fungal bezoar. *Urol Int* 2007; 78(4): 374–376.
2. **Sundi D, Tseng K, Mullins JK, Marr KA, Hyndman ME.** Invasive fungal bezoar requiring partial cystectomy. *Urology* 2012; 79(2): e21–22.
3. **Wainstein MA, Graham RC Jr, Resnick MI.** Predisposing factors of systemic fungal infections of the genitourinary tract. *J Urol* 1995; 154: 160–163.