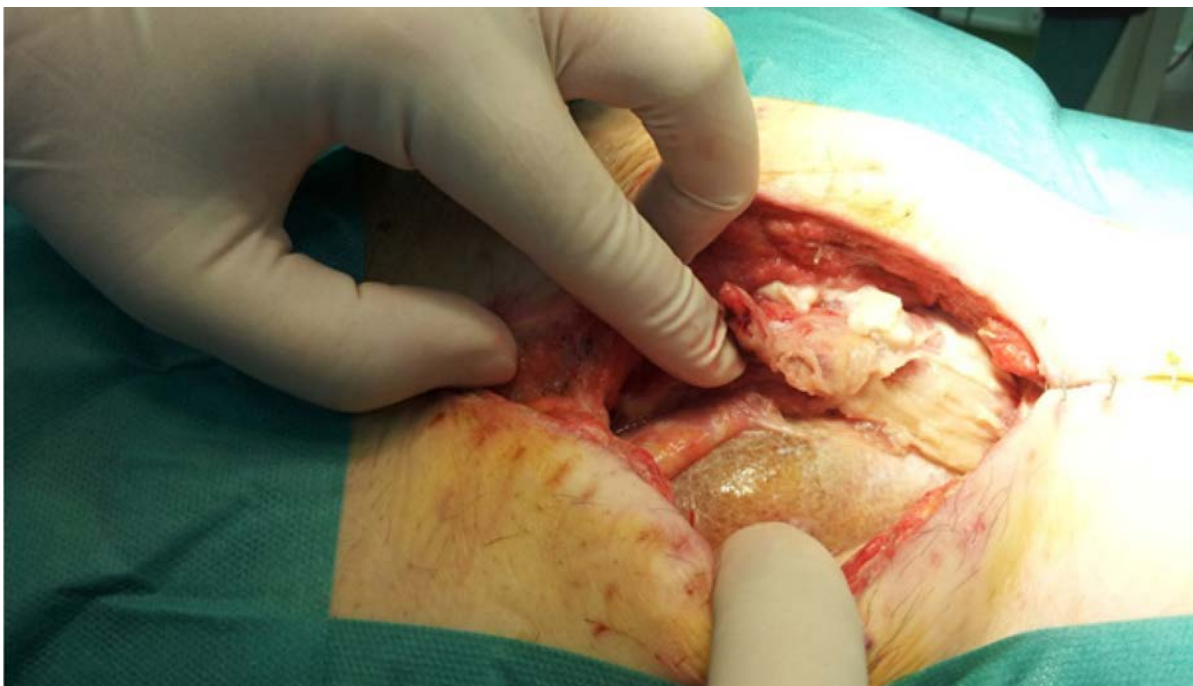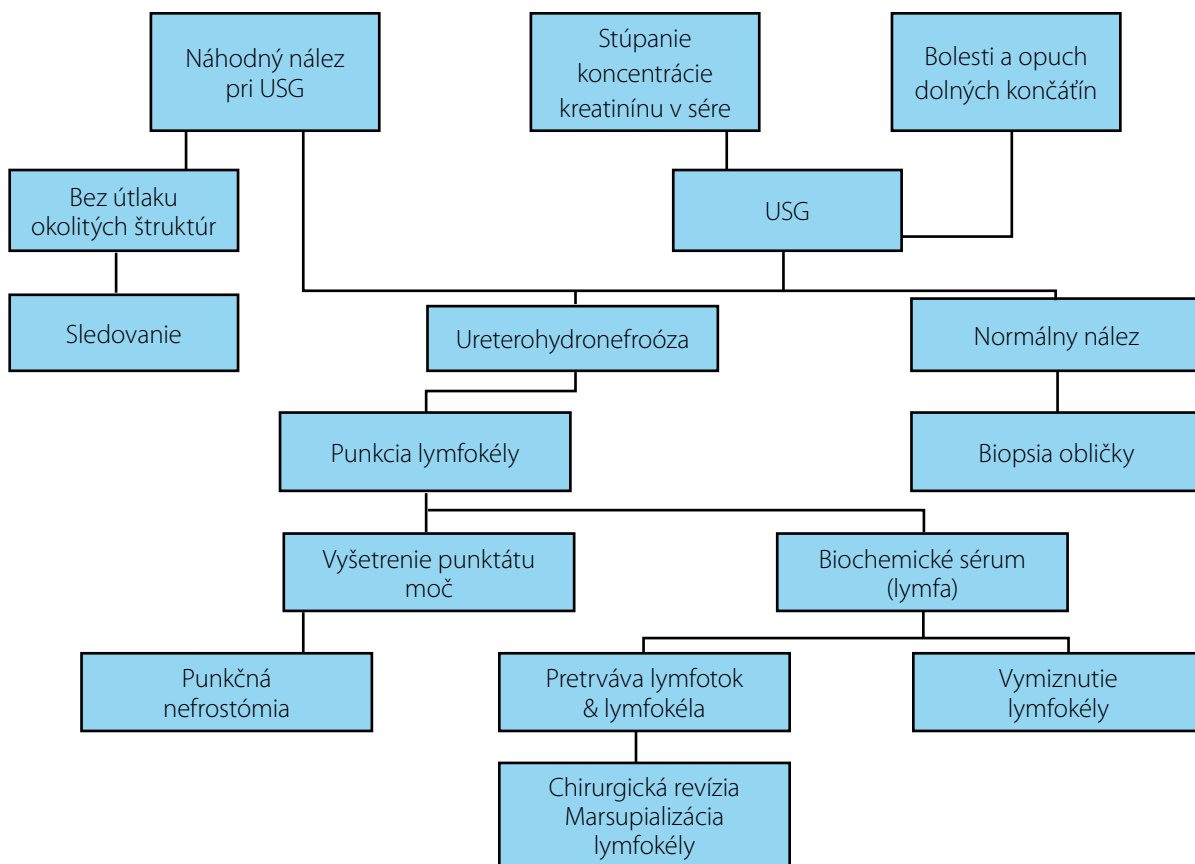


**Obr 4.** Typická žltosfarbená lymfokela pri otvorenej revízii

**Fig. 4.** Typical yellow coloured lymphocele at open revision



**Graf 2.** Algoritmus liečby lymfokély po transplantácii obličky

**Graf 2.** Algorithm of lymphocele treatment after kidney transplantation